

CAPO BULK FILL
plus
Systhetics

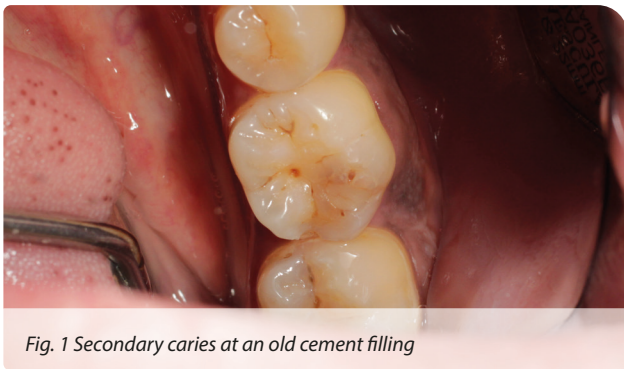
PrimeBond7
Systhetics

Aesthetic final result

Aesthetic renewal of an old cement filling

with Capo Bulk Fill Plus and PrimeBond7

A user report by dentist Dr. Marielle Falkenberg, Cologne



Initial Situation

The 41-year-old patient first came to our dental office for a routine examination in January 2020. During this examination, the following was discovered:

- 36 showed secondary caries at an old cement filling (Fig. 1).

SCHÜTZ DENTAL
Micerium Group

Schütz Dental GmbH • Dieselstr. 5-6 • 61191 Rosbach/Germany • Tel. +49 (0) 6003 814-0 • Fax +49 (0) 6003 814-906
www.schuetz-dental.de • info@schuetz-dental.de

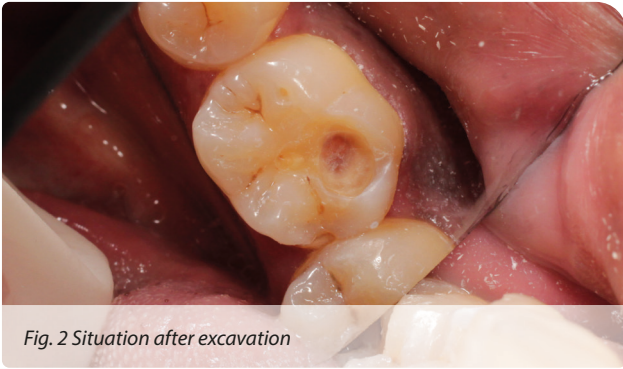

Fig. 2 Situation after excavation

Situation after excavation

The old cement filling, including the secondary caries, was removed while ensuring that as little enamel as possible was taken out (Fig. 2).

Selective enamel etching under rubber dam

To obtain dry and hygienic preconditions, further treatment was carried out with a rubber dam (Fig. 3).

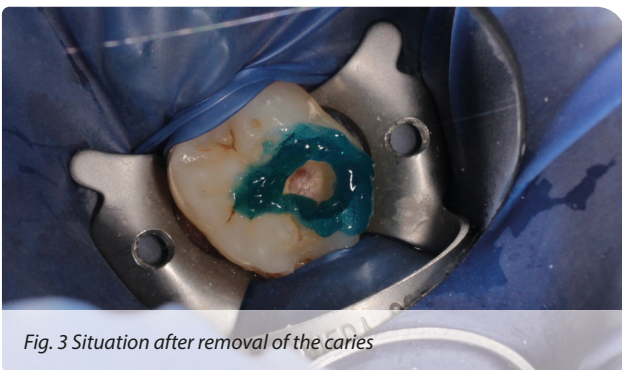

Fig. 3 Situation after removal of the caries



Fig. 4 Applying PrimeBond7 with micro-brush

Use of PrimeBond7

PrimeBond7 was now applied in the open cavity with a micro-brush. The application was extremely simple and used little material (Figs. 4 and 5).

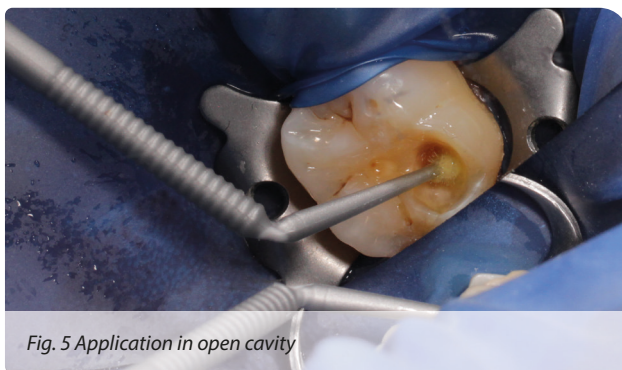

Fig. 5 Application in open cavity

After being rubbed in for 20 seconds, the material was blown on until there was no more excess left (Fig. 6).

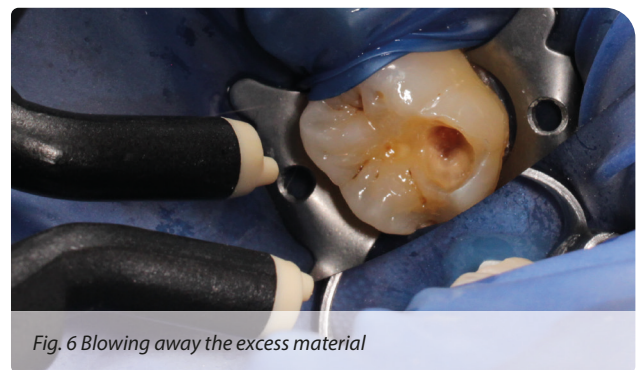

Fig. 6 Blowing away the excess material

Filling the cavity with Capo Bulk Fill Plus

Now the cavity was filled with the first layer of the light curing filling composite Capo Bulk Fill Plus, with a layering thickness of 4 mm (Fig. 7).

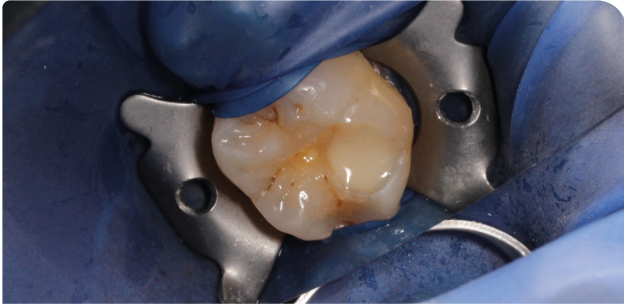


Fig. 7 First layer of Capo Bulk Fill Plus (4 mm)

After the material was cured for 20 seconds (Fig. 8), a second layer of Capo Bulk Fill Plus followed (Fig. 9).



Fig. 8 Light curing for 20 seconds

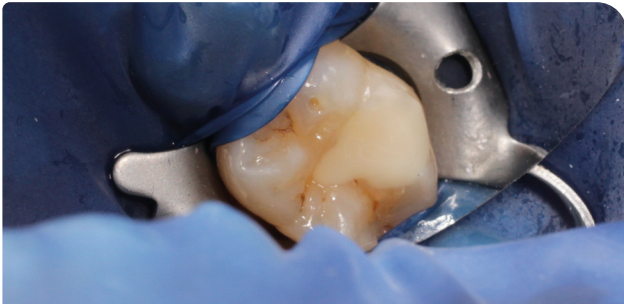


Fig. 9 Second layer of Capo Bulk Fill Plus

Final result

The second layer of Capo Bulk Fill Plus was also light-cured, then finished and polished. The result shows an aesthetic restoration (Fig. 10).

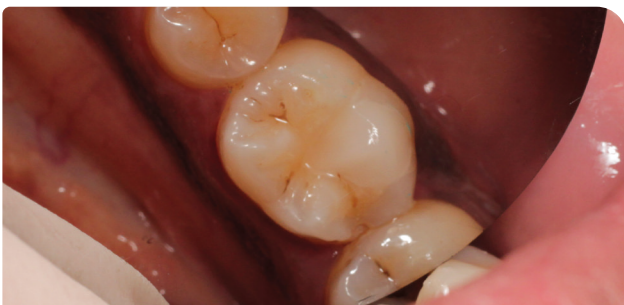

Fig. 10 Finished and polished result

Conclusion

Working with Capo Bulk Fill Plus and Prime-Bond7 is uncomplicated and a good result can be achieved quickly.

Capo Bulk Fill Plus impressed me in particular with its excellent handling. In addition, I noticed while contour-shaping the cured filling that the material shows very high strength. This is probably because of the very high percentage of filler content for a flow composite.

For my everyday work in the dental office, it is important to be able to rely on my base materials in particular, such as composite and bonding systems. Fast, easy and straightforward handling is vital for me here. And that is exactly what convinced me with Capo Bulk Fill Plus and PrimeBond7.

The Author

Dr. Marielle Falkenberg, dentist



Praxis Dr. Dr. Lingohr, Cologne

Range of treatments:

- Aesthetic dentistry
- Endodontics
- Restorative dentistry
- Pedodontics

Schütz Dental online!
www.schuetz-dental.de