

Aesthetic outcome

Cervical Fillings

with PrimeBond7 and Capo Slow Flow

A case study by dentist Dr. Marielle Falkenberg, Cologne/Germany

Initial Situation

During a patient's routine check, we found recessions with v-shaped defects on second and third quadrant teeth.

The cervical fillings were placed with the 7. generation bonding agent PrimeBond7 and the filling composite Capo Slow Flow, both by Schütz Dental GmbH.

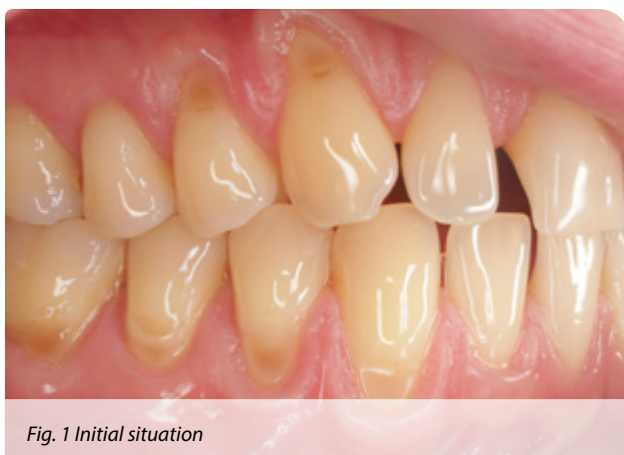

Fig. 1 Initial situation

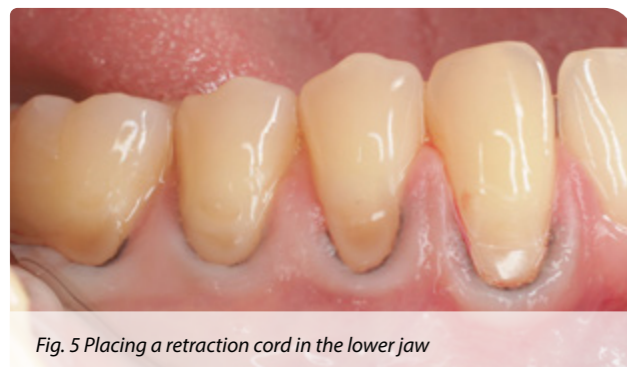
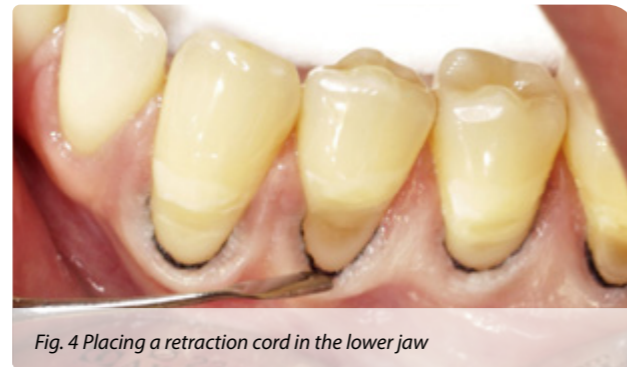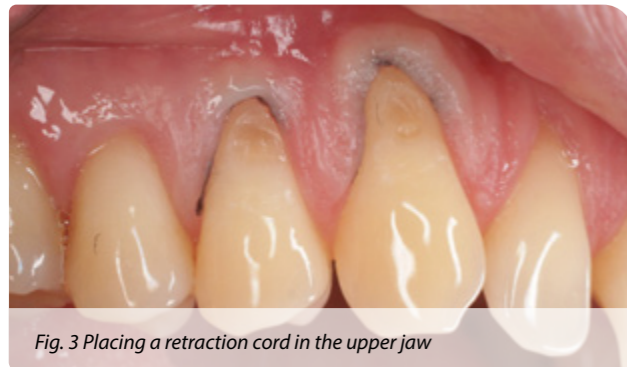


Fig. 2 Capo Slow Flow & PrimeBond7

Exposed Tooth Necks

In a first step, the secondary caries was removed and the cavity was properly prepared. The softened and infected dentin was completely removed, making certain that as little enamel erosion as possible was caused on the

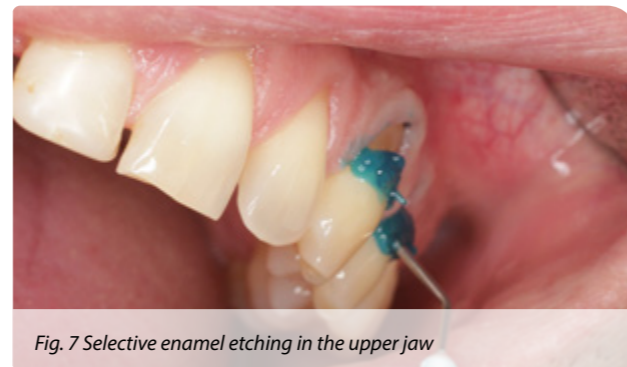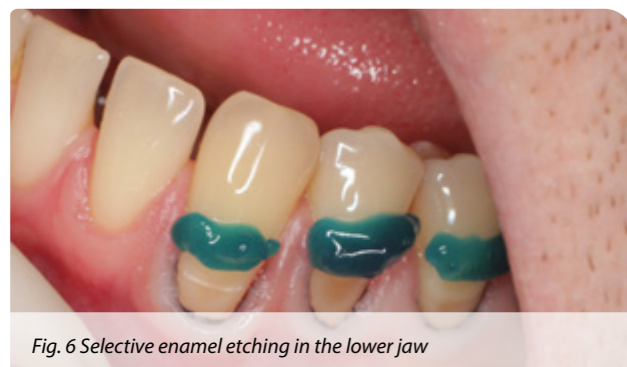healthy part of the natural tooth. In a second step, the enamel was roughened and a retraction cord was placed in each the upper and the lower jaw.



Selective Enamel Etching

Prior to the application of the 7. generation bonding PrimeBond7, the enamel was conditioned with 35 % phosphoric acid for 60 seconds.

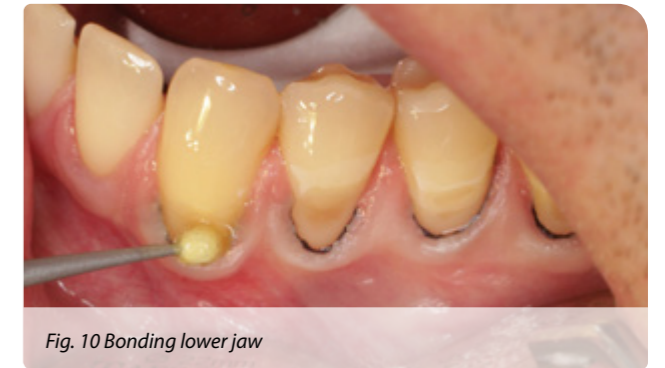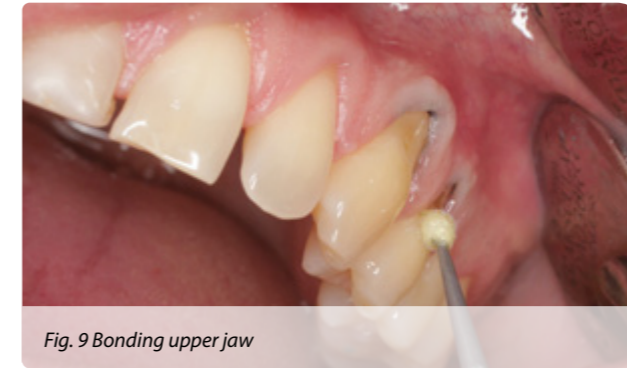PrimeBond7 can be applied either in the selective etch technique or in the self etch technique. We decided to apply the selective etch technique.



Bonding with PrimeBond7

PrimeBond7 was applied conventionally with a micro brush. The material was brushed in for 20 seconds, then

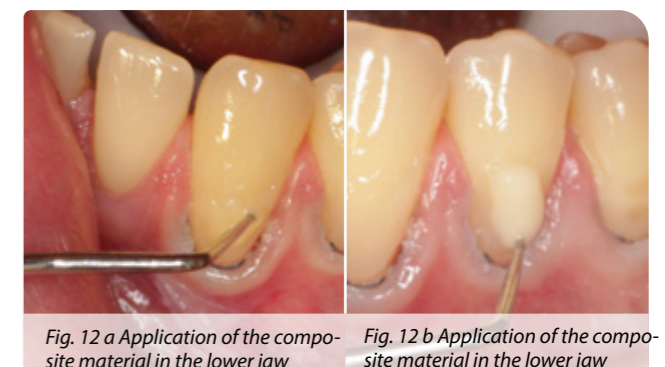
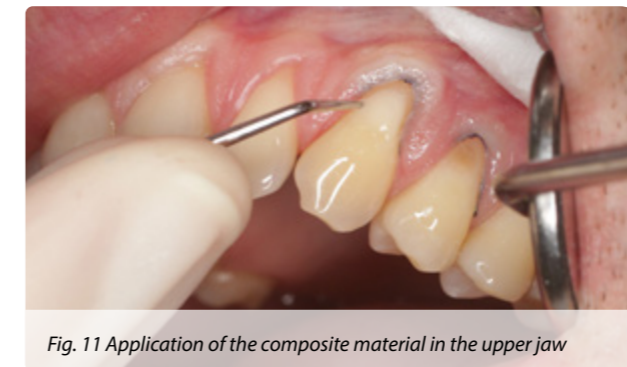it was gently blown with air until no residue was left.



Filling with Capo Slow Flow

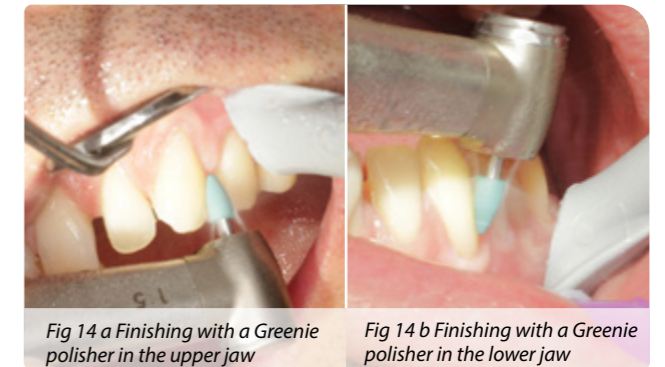
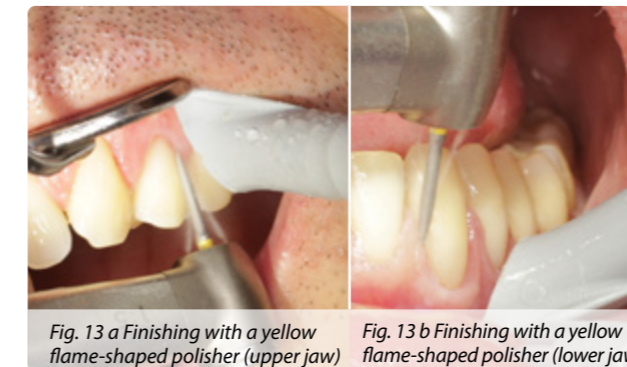The filling material was applied with a probe. Thanks to its good stability, Capo Slow Flow was easy to apply

precisely up to the preparation margins in the upper and lower jaw.



Finishing

The fillings were finished with a yellow flame-shaped polisher and a Greenie polisher in the upper and lower jaws.



Final Result

At the end of the treatment, the Okklubrush was used for the high-gloss polish. The treatment was performed

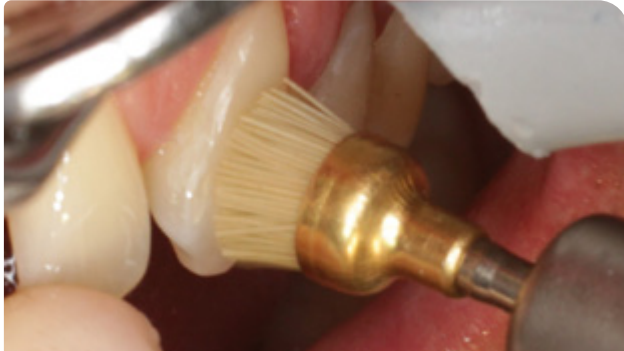

Fig. 15 Finishing with Okklubrush in the upper jaw

in one session. The result shows an aesthetic restoration.

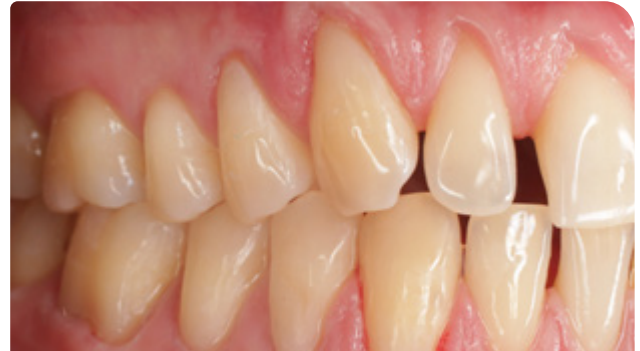

Fig. 16 Final aesthetic result after polishing

The Author



Dentist Dr. Marielle Falkenberg

Range of treatment:

- Aesthetic Dentistry
- Endodontics
- Restorative Dentistry
- Pediatric Dentistry

Conclusion

I have been working with Schütz Dental materials for quite some time. This is my third user report on PrimeBond7 in combination with a restorative composite by Schütz Dental - in this case Capo Slow Flow.

One notices right away the outstanding coordination of this system of products. These materials match magnificently and they have thrilled me again and again, especially with their comfortable handling. Both simple and more complicated patient cases can be treated excellently.

As already described in my previous user report, above all, it is extremely important for me in everyday practice that I can rely on my basic materials such as composite and bonding systems. For me, a fast, easy and problem-free handling is indispensable. PrimeBond7 and Capo Slow Flow have definitely convinced me.

Schütz Dental online!
www.schuetz-dental.com

SCHÜTZ DENTAL
Micerium Group